

**ECTRIMS 2017**  
Paris. October 25, 2017  
NAIMS/MAGNIMS ACTRIMS/ECTRIMS Teaching Course  
Imaging the non-MS lesion in MS

**“Atypical imaging presentations of MS and other idiopathic demyelinating diseases”**

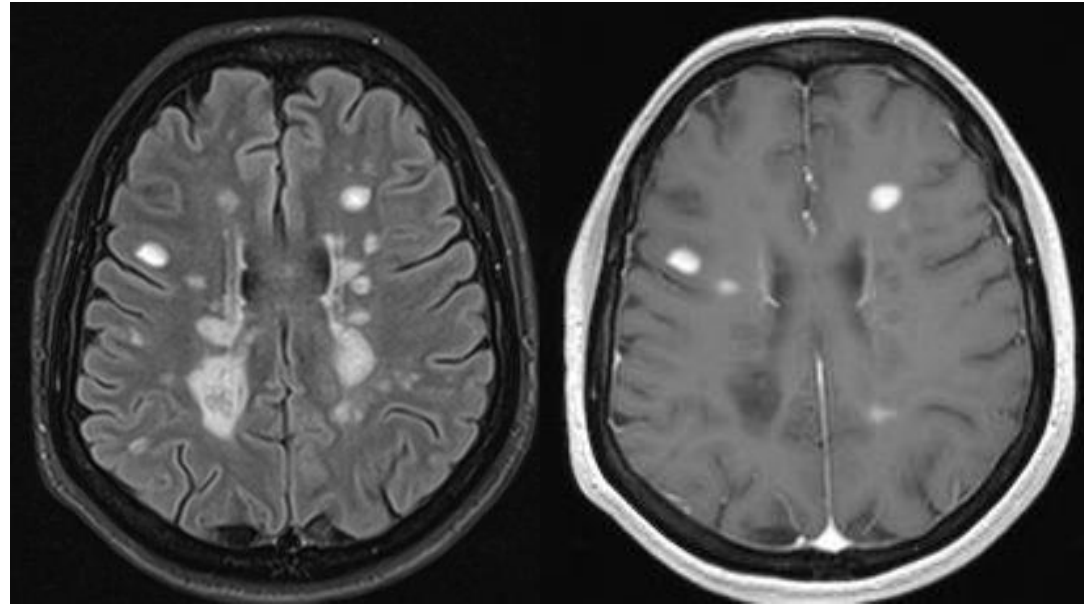


*Àlex Rovira*  
*Secció de Neuroradiologia. Servei de Radiologia*  
*Hospital Universitari Vall d'Hebron*  
*Barcelona*  
*alex.rovira@idi.gencat.cat*



# MR imaging in MS and other IDD

T2-weighted  
(FLAIR)



Post-contrast  
T1-weighted

- Highly sensitive for detecting lesions (white matter)
- Provide quantitative assessment of disease activity and severity
- Characterize disease course over time
- Monitor and predict treatment response
- Most important paraclinical tool for diagnosing and monitoring MS and other IDD

# Multifocal WM signal abnormalities: “white spots”

## Incidental finding

aging (80-100%)  
normal young adult population (5-10%)  
migraine (x4)  
Virchow-Robin spaces

## Hypoxic-ischemic vasculopathies

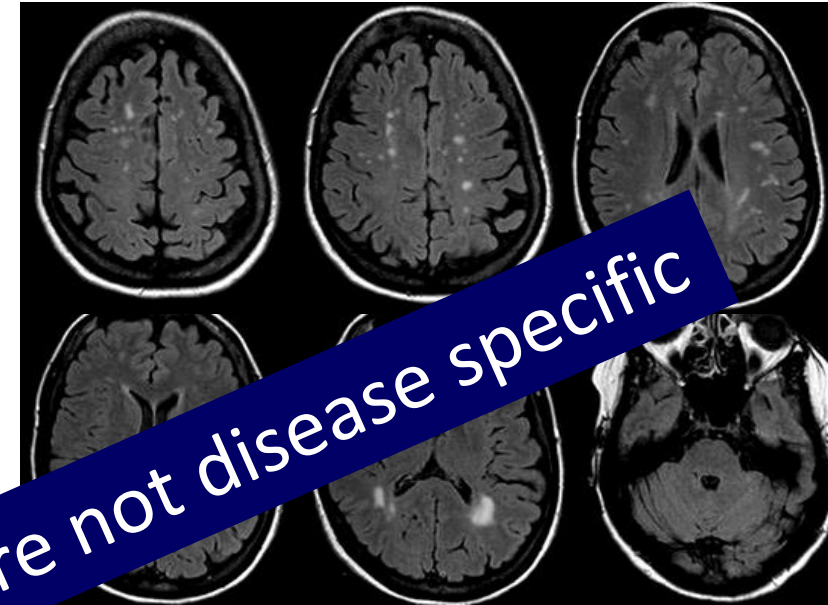
Lipohyalinotic small-vessel disease  
Cerebral amyloid angiopathy  
Genetic vascular disorders: CADASIL

## Primary demyelinating diseases

multiple sclerosis and variants  
ADEM  
neuromyelitis optica

## Vasculitis

primary  
systemic: *lupus, Behçet, APLAS*



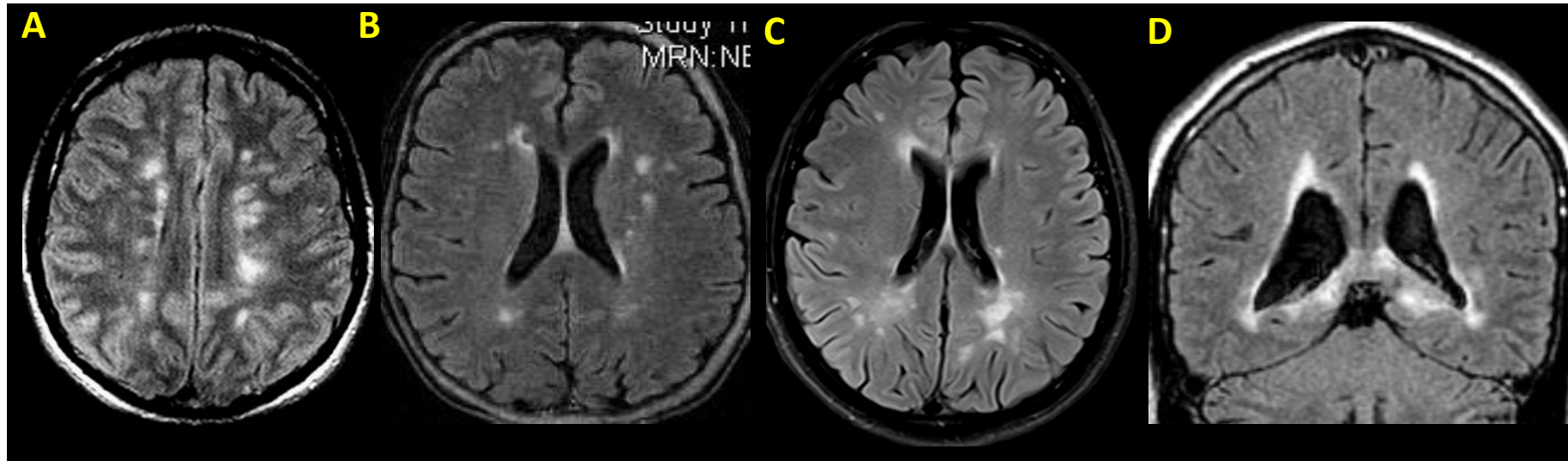
## Miscellaneous

neurosarcoidosis  
Lyme disease  
PML  
metabolic: Leber, xantomatosis, adult forms of leukodystrophy  
effects of radiation therapy or drugs  
lymphoma  
metastatic disease

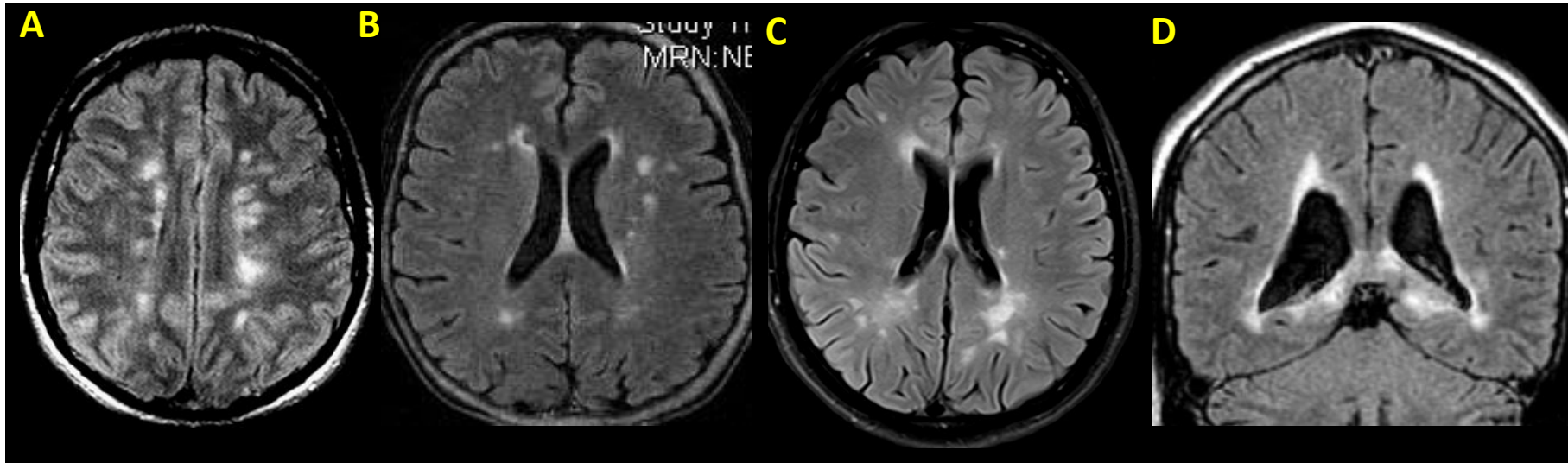
# Multifocal WM signal abnormalities: “white spots”

- Evaluation of focal white matter hyperintensities (WMH) on MRI is always challenging (particularly in young patients)
- Their cause may vary from infectious, inflammatory, neoplastic, or demyelinating findings to nonspecific findings related to aging and other systemic conditions

Sánchez Aliaga E, Barkhof F. Handb Clin Neurol 2014;122:291-316; Charil et al. Lancet Neurol 2006;5:841-52



# MCQ1

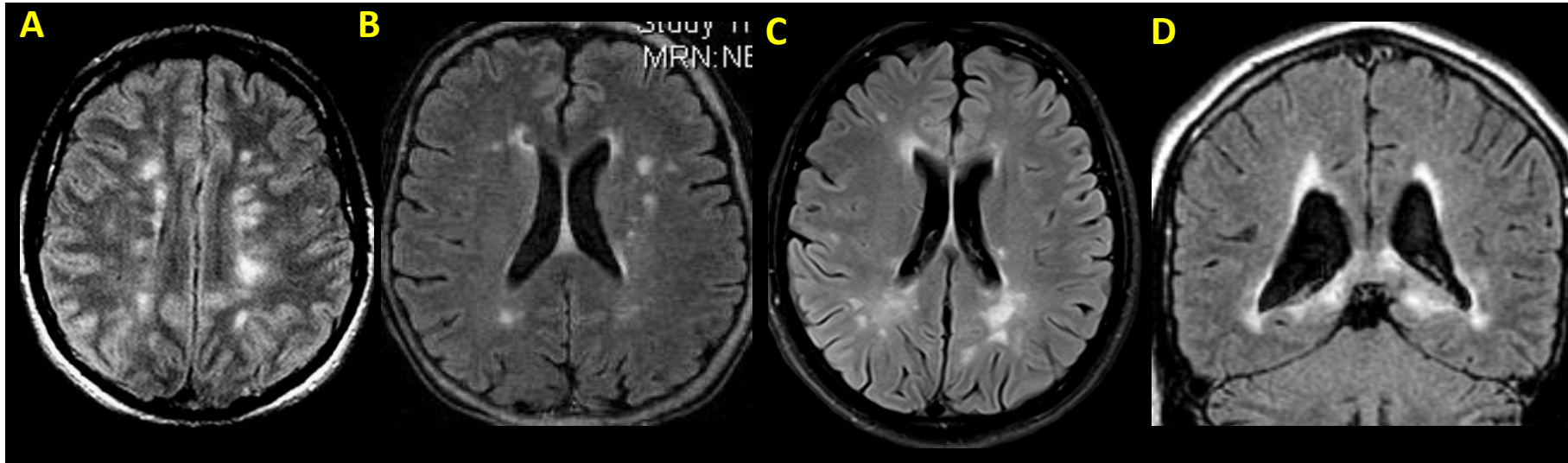


Indicate which of these four patients has Multiple Sclerosis:

1. A
2. B
3. C
4. D



# MCQ1



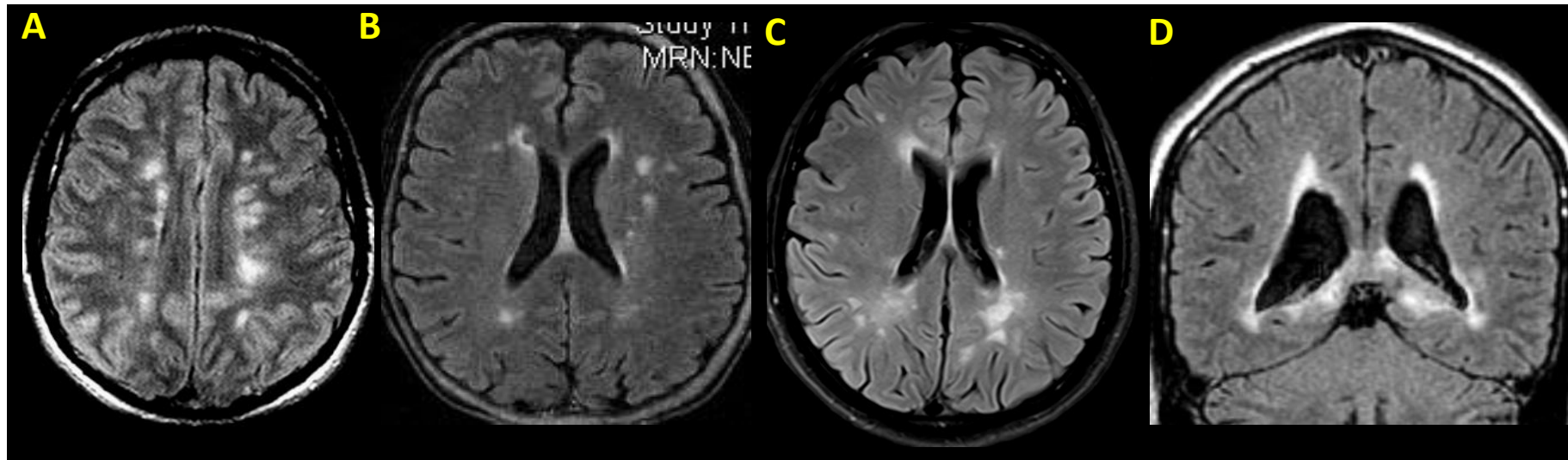
Indicate which of these four patients has Multiple Sclerosis:

1. A
2. B
3. C
4. D

# Multifocal WM signal abnormalities: “white spots”

- Evaluation of focal white matter hyperintensities (WMH) on MRI is always challenging (particularly in young patients)
- Their cause may vary from infectious, inflammatory, neoplastic, or demyelinating findings to nonspecific findings related to aging and other systemic conditions

Sánchez Aliaga E, Barkhof F. Handb Clin Neurol 2014;122:291-316; Charil et al. Lancet Neurol 2006; 5: 841–52



Fat embolism

Lyme disease

Multiple sclerosis

Neurosarcoidosis

# Diagnostic strategy in subjects with incidental multifocal brain T2 lesions of unknown origin

## Comprehensive checklist for evaluation of WM spots

### Systematic reading

- **Lesion distribution / involvement**

- ✓ subcortical/periventricular
- ✓ U-fibers
- ✓ cortical grey matter
- ✓ deep grey matter
- ✓ corpus callosum
- ✓ brainstem
- ✓ spinal cord

- **Enhancement pattern**

- **Lesion shape**
- **Central vein sign**
- **Intralesional susceptibility signal**

### Brief and precise diagnostic impression that must consider:

- ✓ Demographics
- ✓ Family history
- ✓ Vascular risk factors
- ✓ Clinical information and question
- ✓ Lab findings



# McDonald 2010 criteria

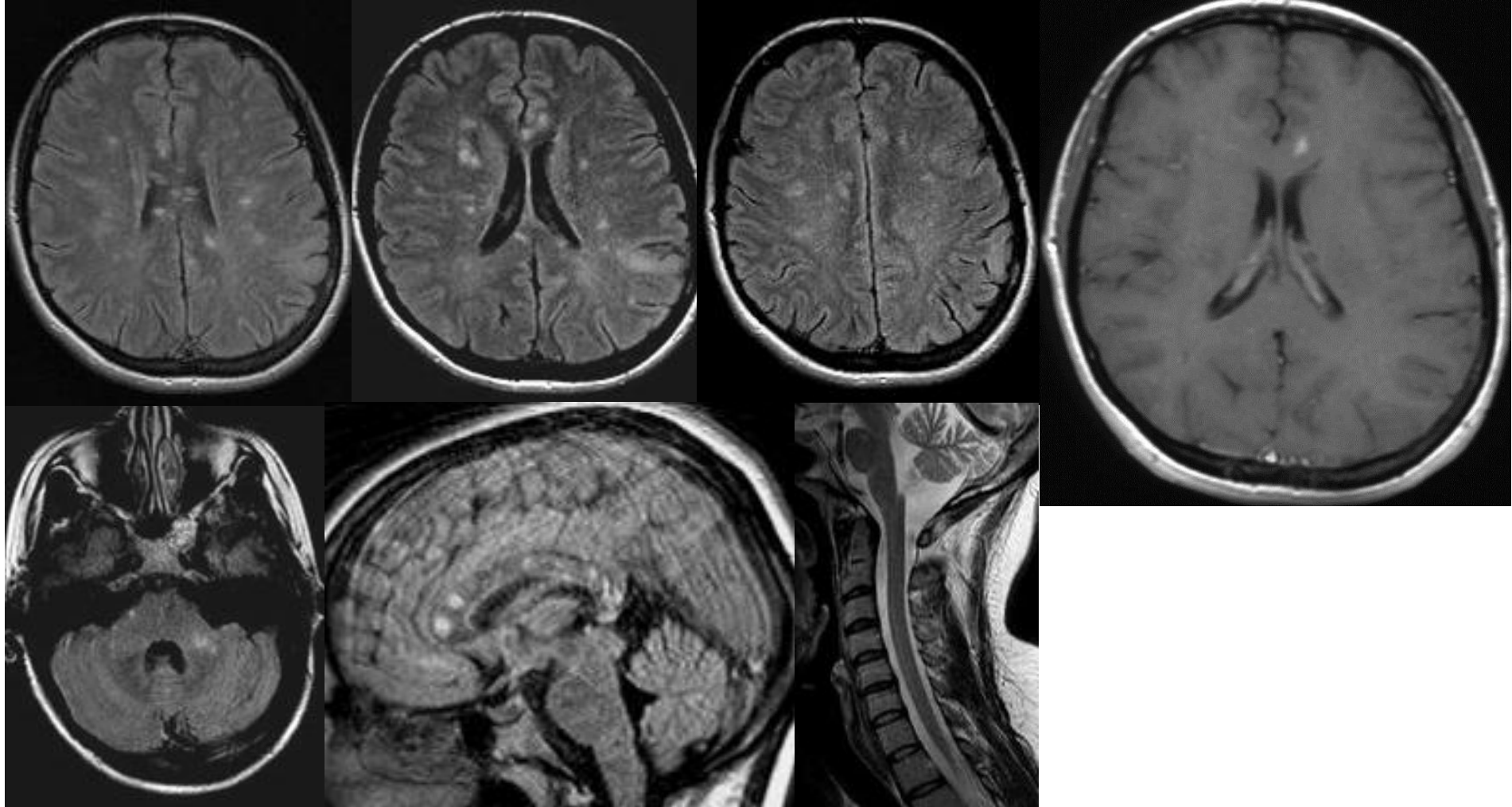
## The McDonald 2010 Criteria

Clinical Attacks <sup>a</sup>	Clinical Evidence of Lesions	Additional Requirements for MS Diagnosis
≥2	Objective clinical evidence of ≥2 lesions or objective clinical evidence of 1 lesion with reasonable historical evidence of a prior attack	None
≥2	Objective clinical evidence of 1 lesion	<b>Dissemination in space</b> , defined as: <ul style="list-style-type: none"> <li>• ≥1 T<sub>2</sub> asymptomatic lesion in ≥2 MS-typical CNS regions; <i>or</i></li> <li>• Await further clinical attack implicating a different CNS site</li> </ul>
1	Objective clinical evidence of ≥2 lesions	<b>Dissemination in time</b> , defined as: <ul style="list-style-type: none"> <li>• Simultaneous asymptomatic Gd-enhancing and non-enhancing lesions at any time; <i>or</i></li> <li>• New T<sub>2</sub> and/or Gd-enhancing lesion(s) on follow-up MRI, irrespective of its timing; <i>or</i></li> <li>• Await a second clinical attack</li> </ul>
1	Objective clinical evidence of 1 lesion (clinically isolated syndrome)	<b>Dissemination in space AND time (as defined above)</b> <ul style="list-style-type: none"> <li>• Requirements can be met by a <i>single MRI scan</i></li> </ul>

<sup>a</sup>An attack (relapse; exacerbation) is defined as patient-reported or objectively observed events typical of an acute inflammatory demyelinating event in the CNS, current or historical, with duration of at least 24 hours, in the absence of fever or infection.

Polman CH et al. *Ann Neurol* 2011;69:292-302.

**33 year-old woman with a three week clinical picture of behavioural disturbance, visual loss, bradypsychia, somnolence, headache, and memory loss**



## MCQ2

Does this patient fulfil the MRI diagnostic criteria for MS?

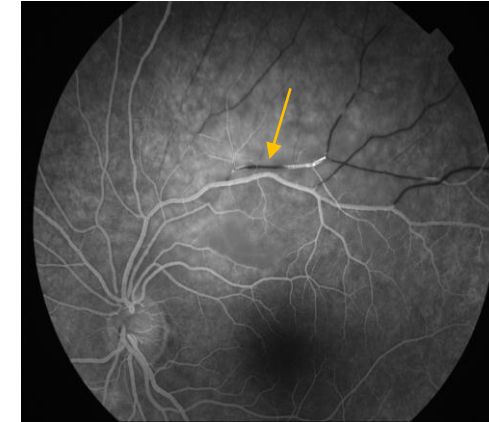
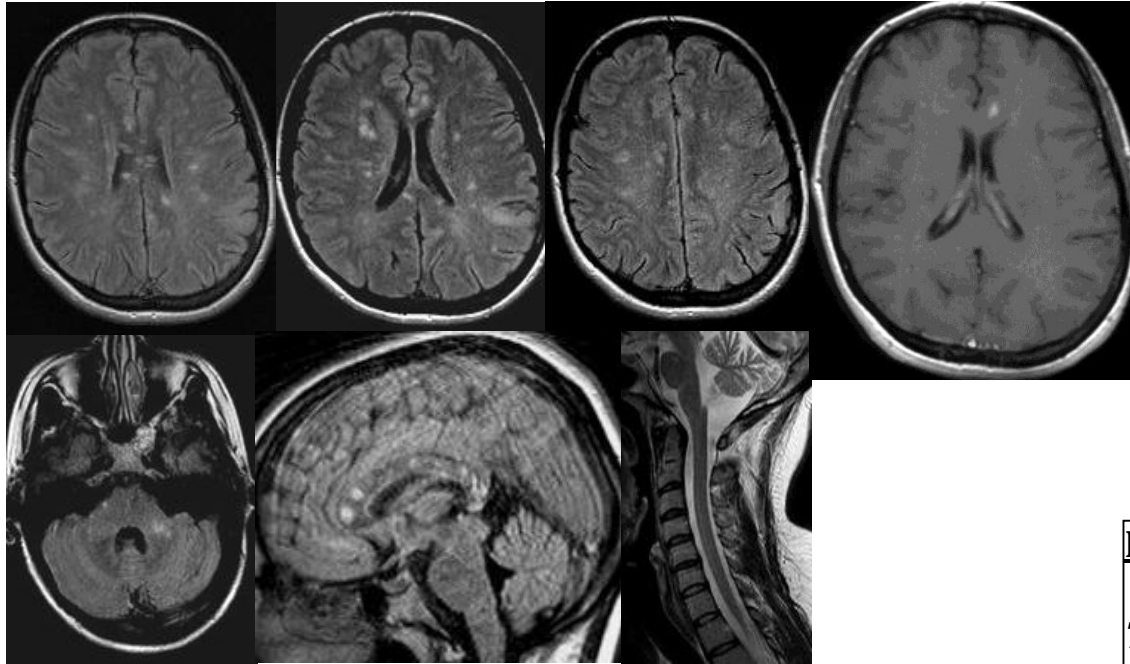
1. Only dissemination in time
2. Only dissemination in space
3. Both dissemination in space and time
4. The MRI criteria cannot be applied

## MCQ2

Does this patient fulfil the MRI diagnostic criteria for MS?

1. Only dissemination in time
2. Only dissemination in space
3. Both dissemination in space and time
4. **The MRI criteria cannot be applied**

**33 year-old woman with a three week clinical picture of behavioural disturbance, bradypsychia, somnolence, headache, and memory loss**



Are the findings suggestive of MS: **NO**

**Susac syndrome**

**Diagnostic criteria**

*Type of CIS:* multifocal

***Dissemination in space*** **Y**

- Juxtacortical y
- Periventricular y
- Brainstem/cerebellum y
- Spinal cord n

***Dissemination in time*** **Y**

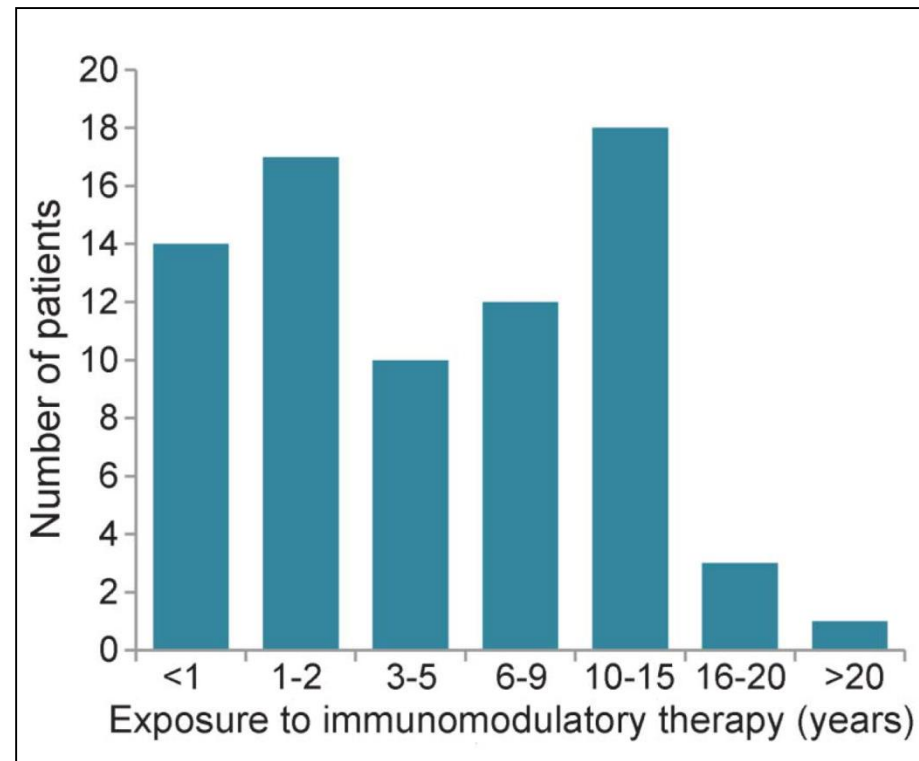
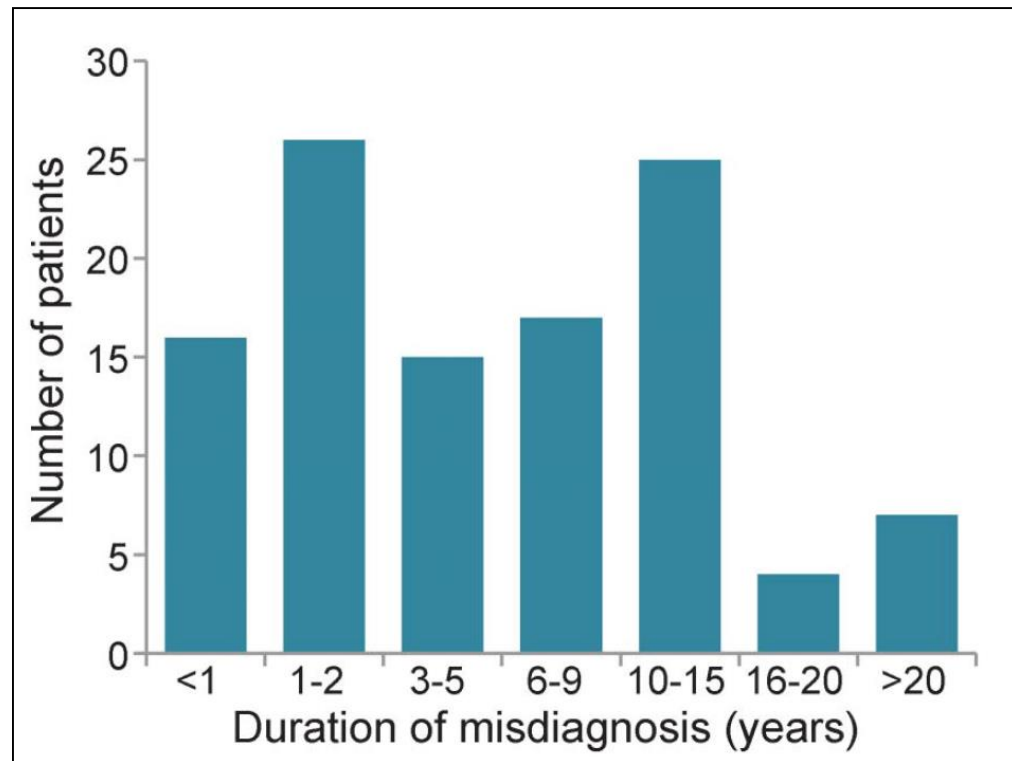
- Enhancing/non enhancing y
- New T2 NA



# Misdiagnosis of Multiple Sclerosis

- Neurologists at 4 academic MS centers submitted data on patients determined to have been misdiagnosed with MS.
- 110 misdiagnosed patients:
  - ✓ 51 (46%) “definite” misdiagnoses
  - ✓ 59 (54%) “probable” misdiagnoses

**70% received  $\geq 1$  DMD**



## MCQ3

Which is in your opinion the main contributor to MS misdiagnosis?

1. Overreliance on the presence of MRI abnormalities meeting DIS to confirm a diagnosis of MS in a patient with “nonspecific or atypical neurologic symptoms”
2. Erroneous determination of juxtacortical or periventricular lesion location to fulfill DIS
3. Erroneous determination of DIT because of variability of MRI slice orientation (i.e., MRIs performed on different scanners leading to the appearance of new lesions)
4. Lack of enough expertise in evaluating MRI scans

Which is in your opinion the main contributor to MS mis diagnosis?

1. Overreliance on the presence of MRI abnormalities meeting DIS to confirm a diagnosis of MS in a patient with “nonspecific or atypical neurologic symptoms”
2. Erroneous determination of juxtacortical or periventricular lesion location to fulfill DIS
3. Erroneous determination of DIT because of variability of MRI slice orientation (i.e., MRIs performed on different scanners leading to the appearance of new lesions)
4. Lack of enough expertise in evaluating MRI scans

# Misdiagnosis of Multiple Sclerosis

## Contributors to MS misdiagnosis

Yes

n (%)

No

n (%)

Unknown

n (%)

**Inappropriate application to MS diagnostic criteria of neurologic symptoms atypical for a demyelinating attack**

**Inappropriate application to diagnostic criteria of a historical episode of neurologic dysfunction without corroborating objective evidence of a lesion (on neurologic examination, evoked potentials, or imaging)**

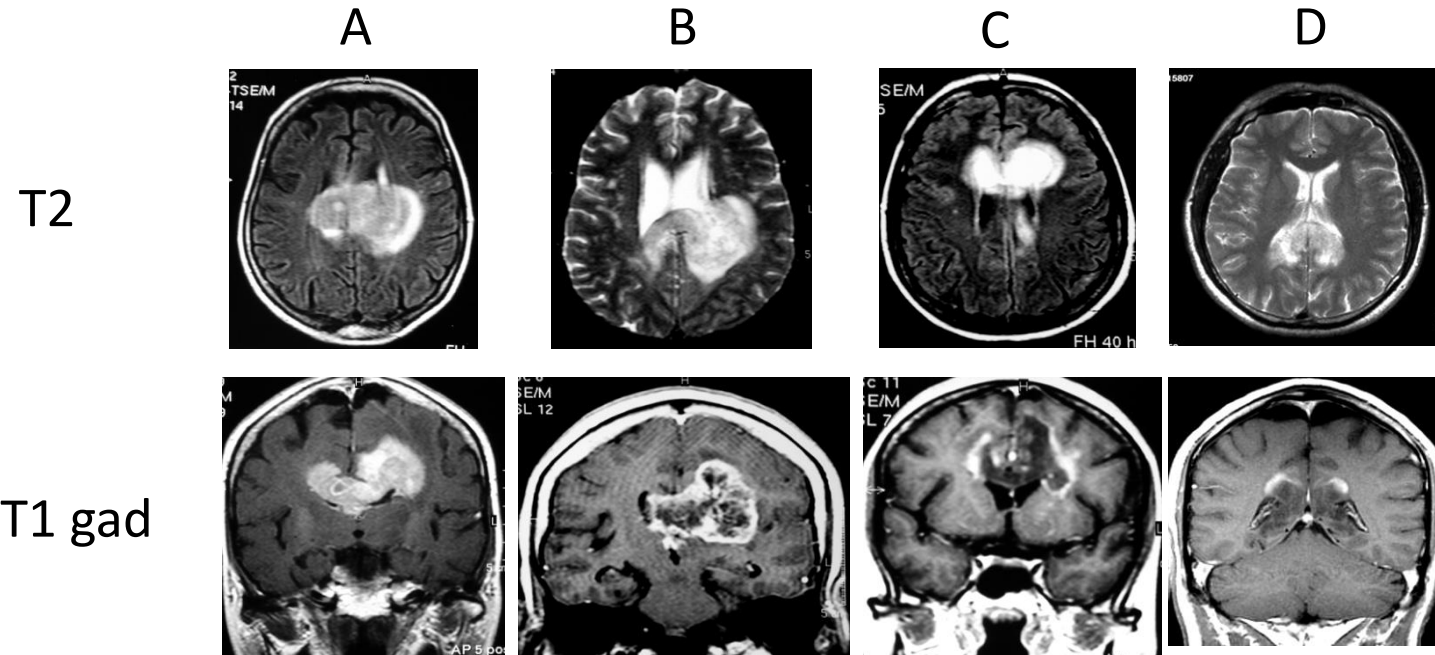
**Overreliance on the presence of MRI abnormalities meeting DIS to confirm a diagnosis of MS in a patient with “nonspecific neurologic symptoms”**

**Erroneous determination of juxtacortical or periventricular lesion location to fulfill DIS**

Neuromyelitis optica spectrum disorder

7 (6)

# Differential diagnosis of tumefactive lesions MCQ4

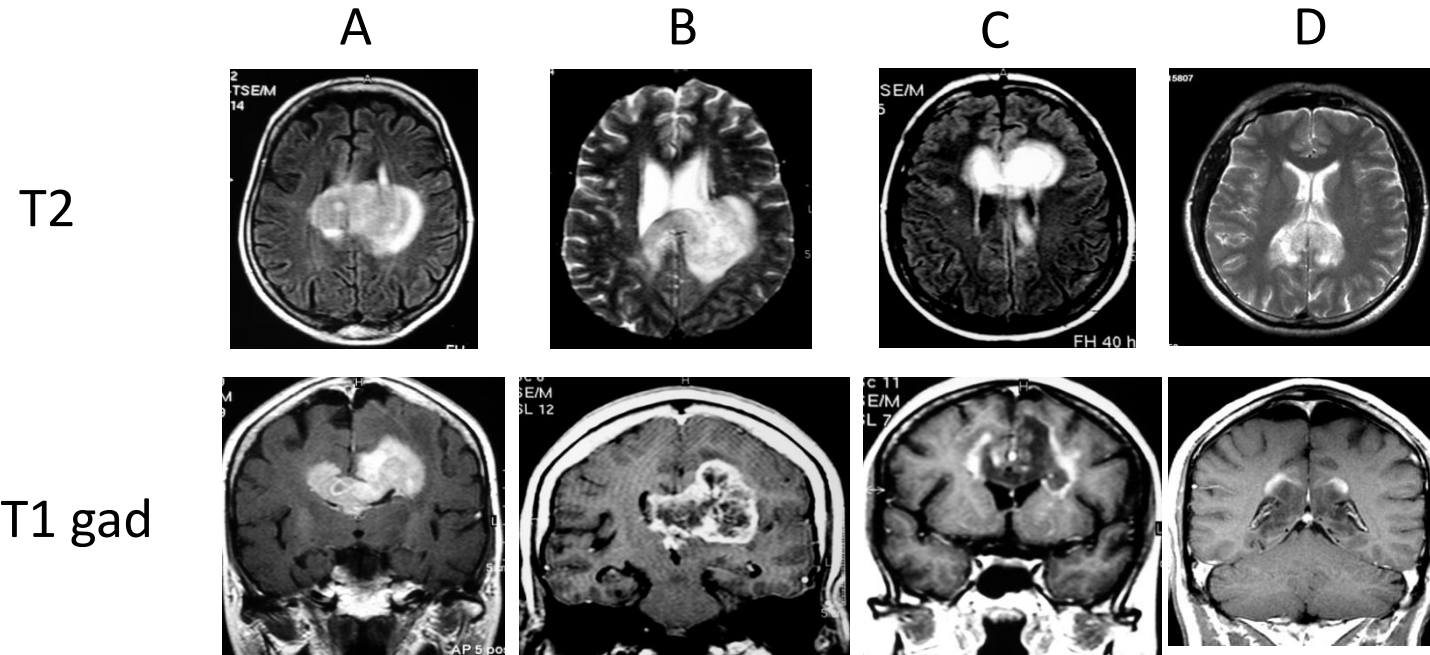


Which of these lesions require a biopsy?

1. A, B and C
2. A and B
3. C and D
4. All lesions



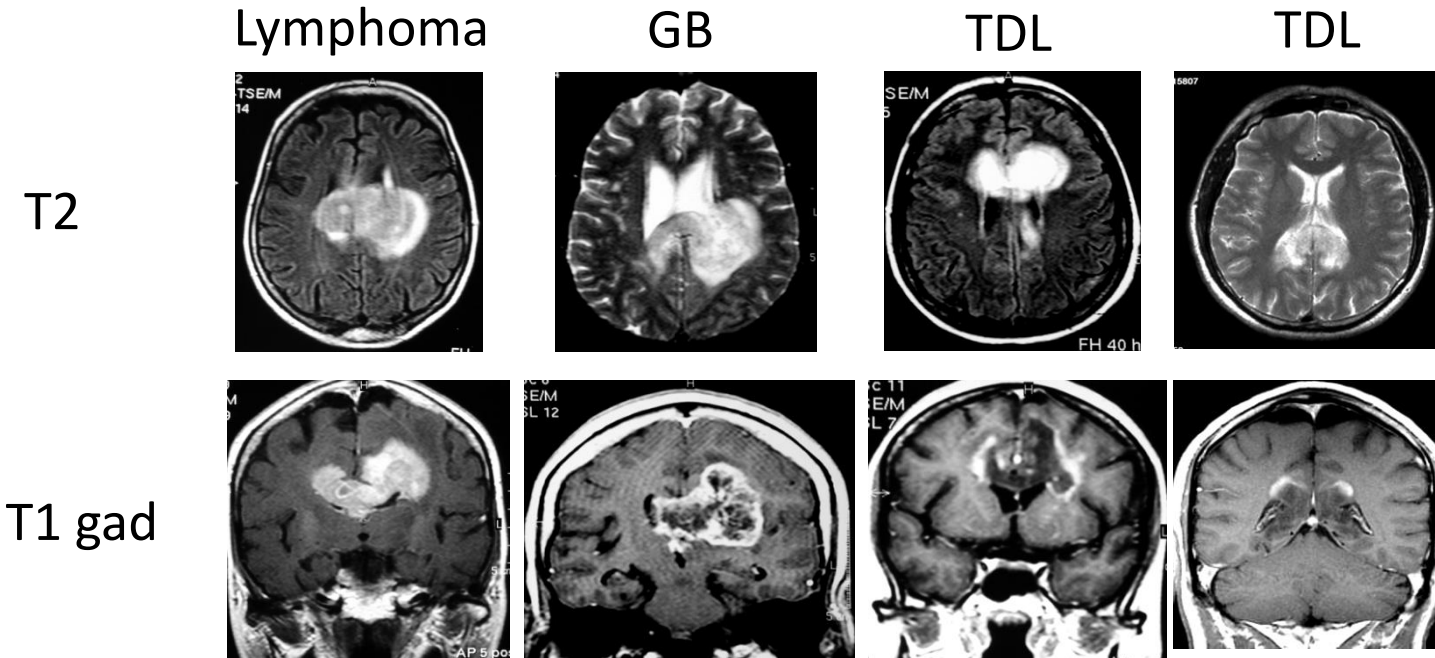
# Differential diagnosis of tumefactive lesions MCQ4



Which of these lesions require a biopsy?

1. A, B and C
2. **A and B**
3. C and D
4. All lesions

# Differential diagnosis of tumefactive lesions MCQ4



Which of these lesions require a biopsy?

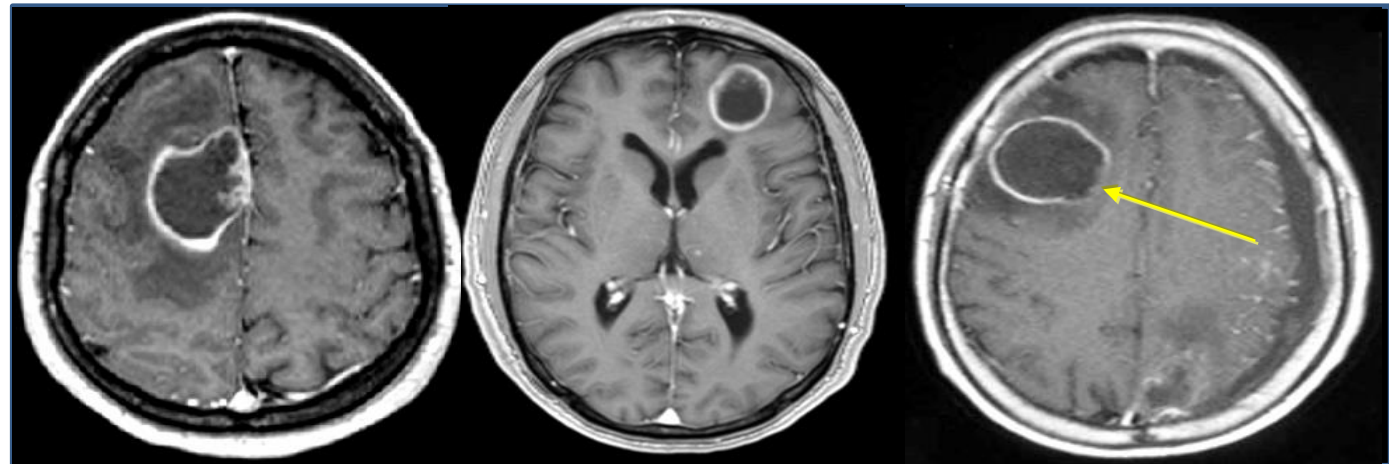
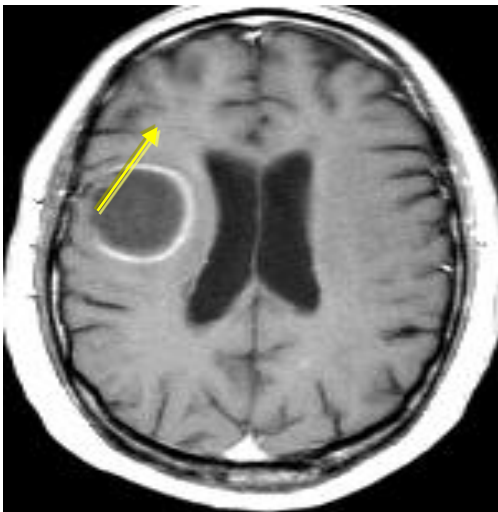1. A, B and C
2. **A and B**
3. C and D
4. All lesions

## Open-ring - enhancement

Incomplete (open) ring enhancement in active MS

open border facing the cortical /deep gray matter

MS



Glioblastoma

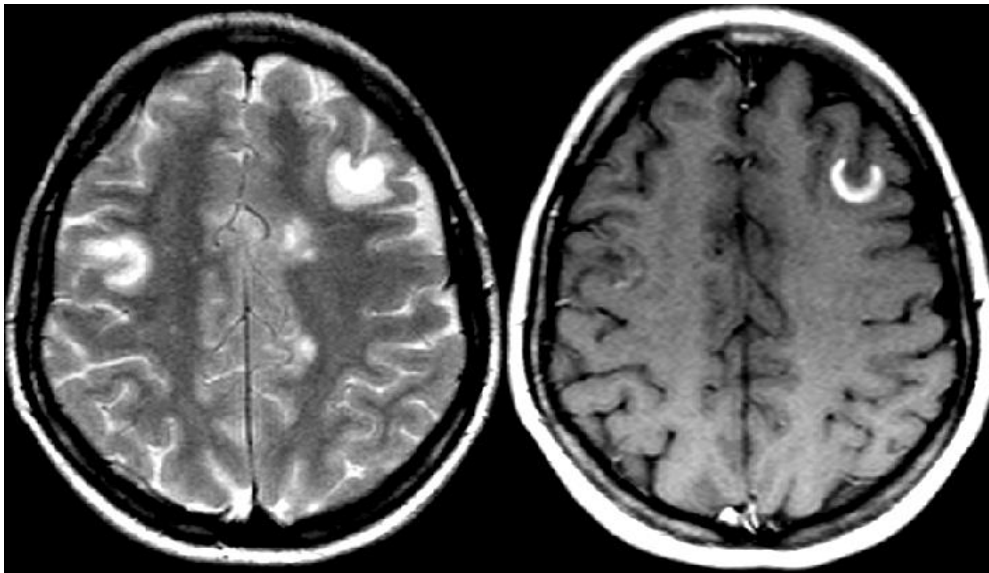
Metastasis

Abscess

## Open-ring - enhancement

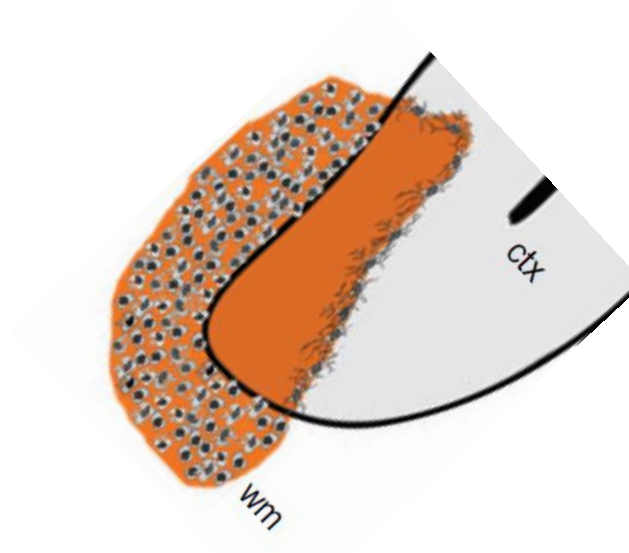
Incomplete (open) ring enhancement in active MS

open border facing the cortical /deep gray matter



## Cortical lesions in MS

Less BBB disruption (no protein leakage)  
Much less macrophage infiltration  
Minimal or absent contrast uptake



Is the presence of open ring enhancement a specific MRI feature for inflammatory demyelinating lesions?

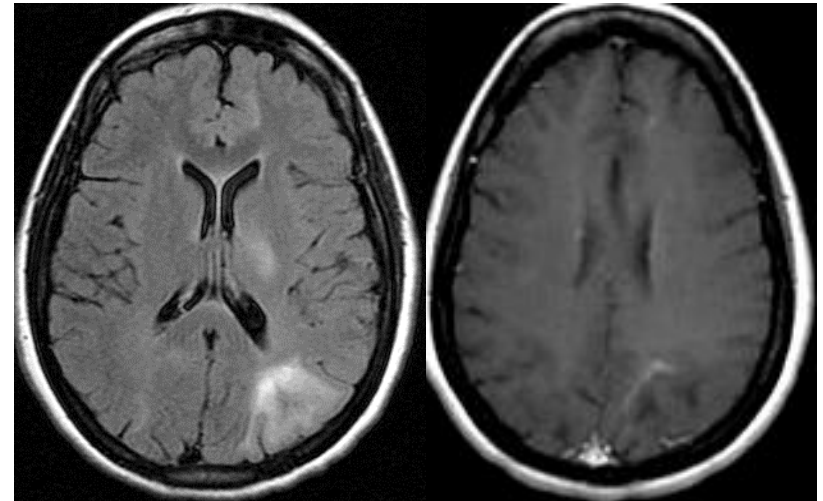
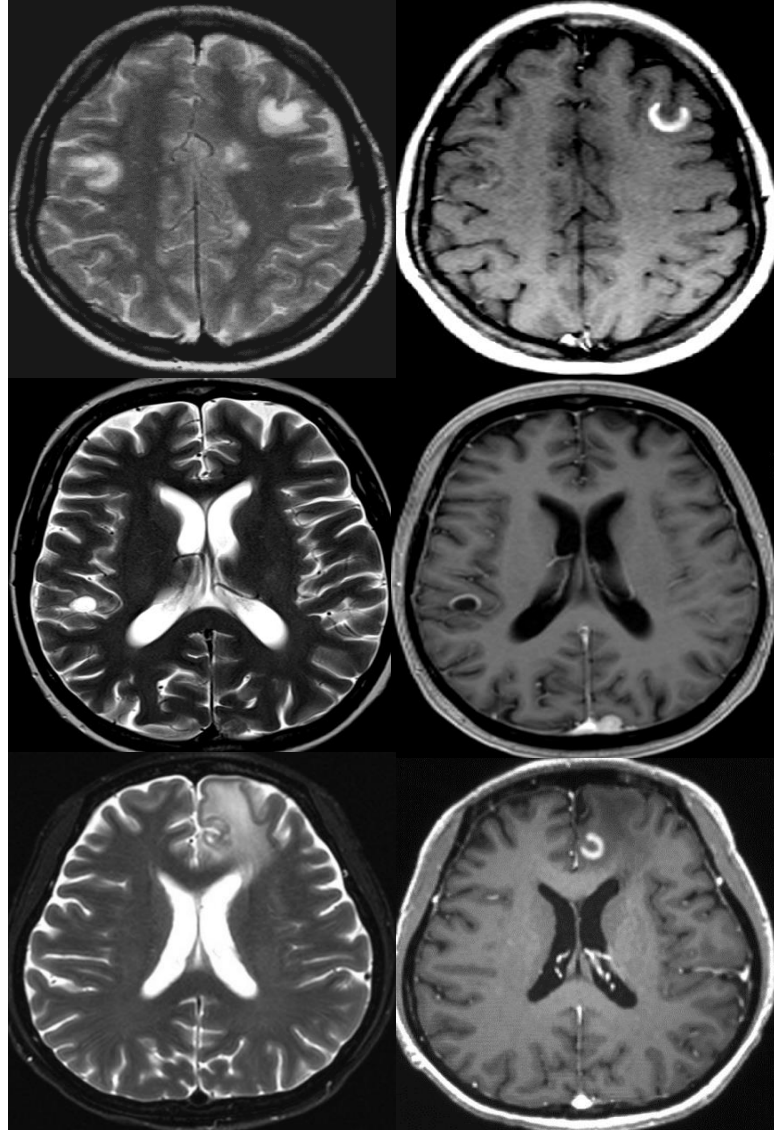
1. Yes, 100%
2. Highly specific
3. Has low specificity
4. Only seen in pseudotumoral IDLs



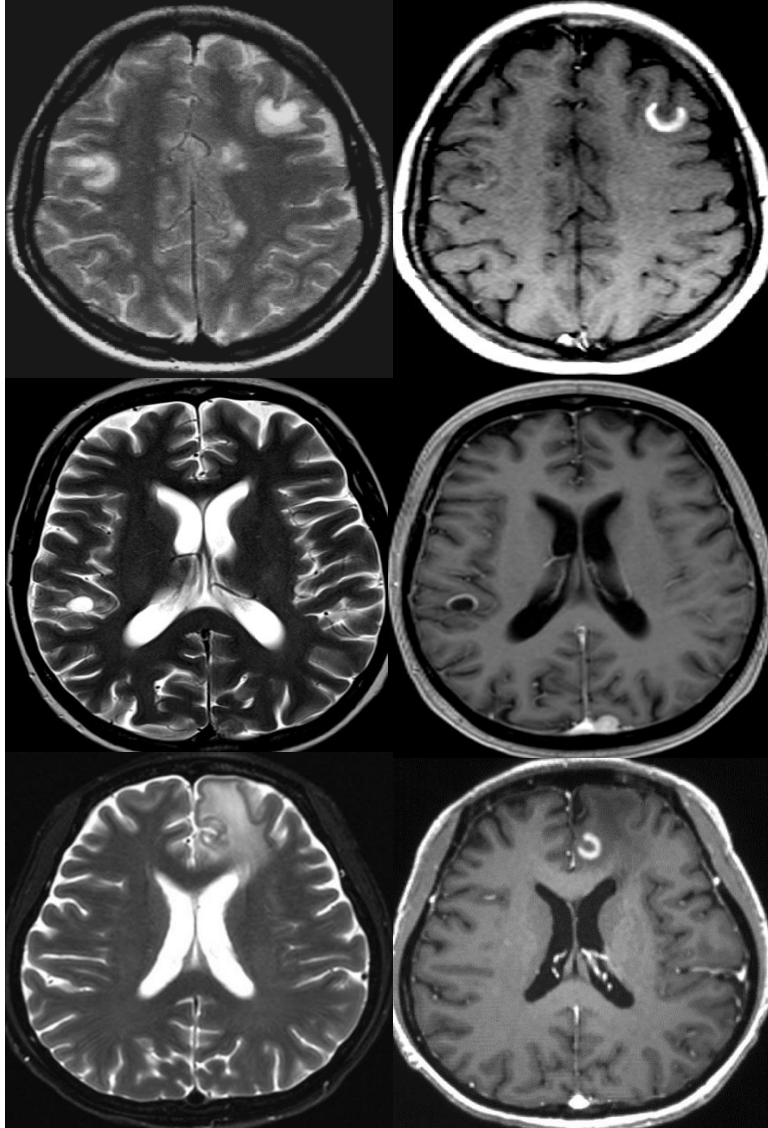
Is the presence of open ring enhancement a specific MRI feature for inflammatory demyelinating lesions?

1. Yes, 100%
2. **Highly specific**
3. Has low specificity
4. Only seen in pseudotumoral IDLs

# Open-ring enhancement



# Open-ring enhancement

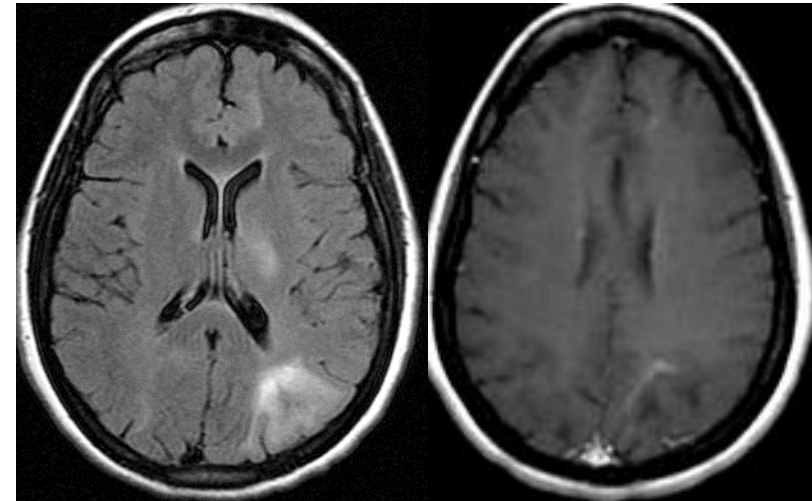


Multiple sclerosis

Metastasis

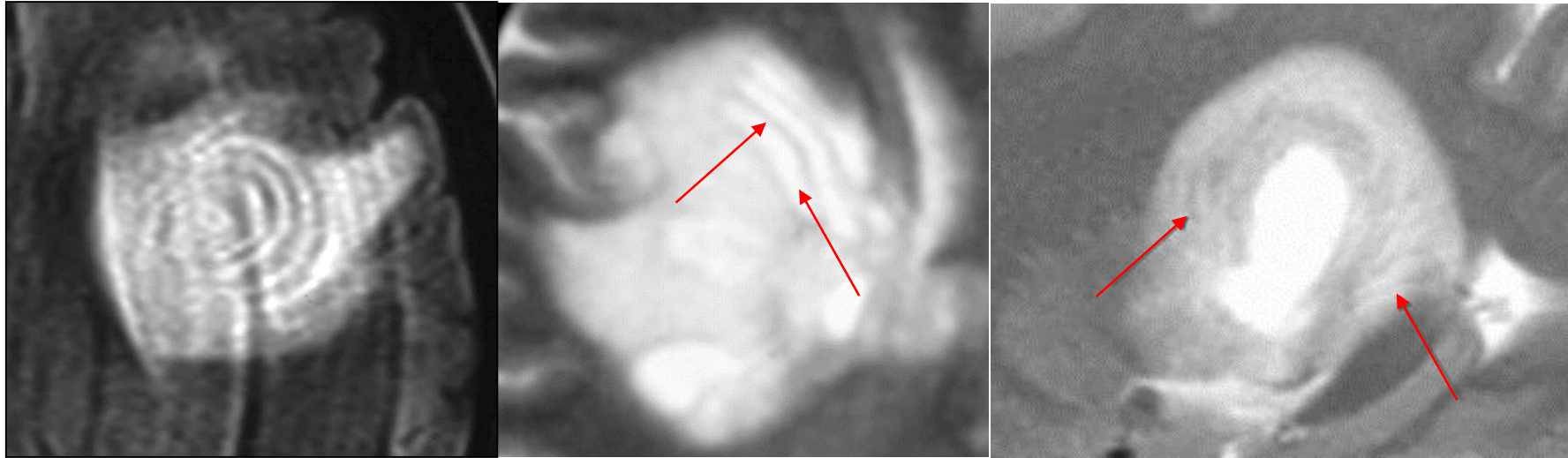
Lymphoma

Courtesy M. Castillo.  
Chapell Hill



PML-Natalizumab

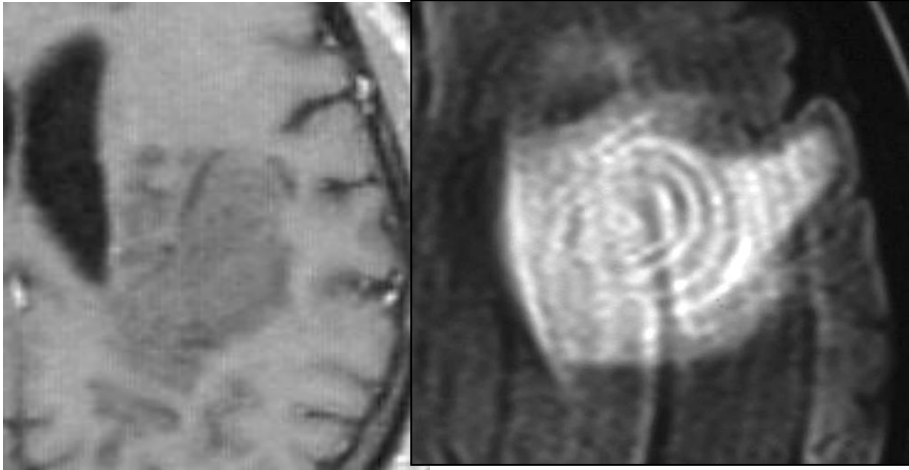
## MR imaging features



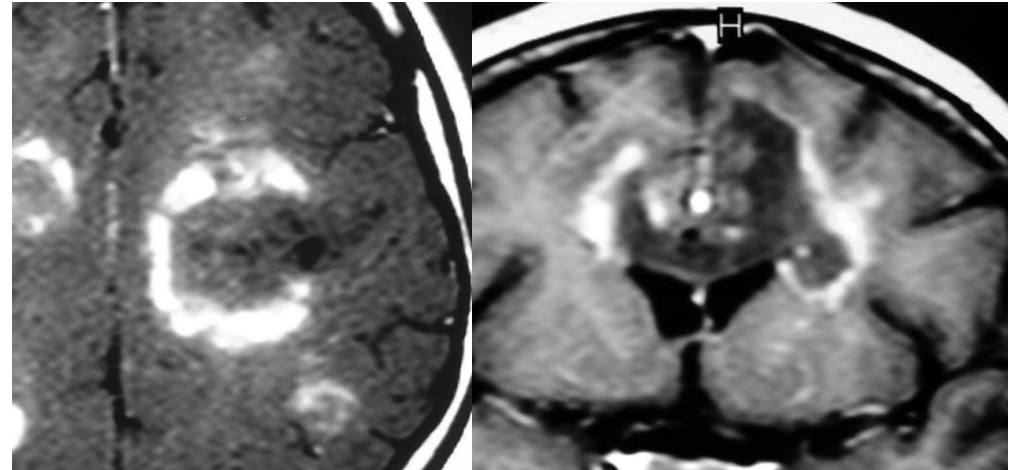
- Multiple concentric layers (onion skin lesions), as a mosaic, or as a “floral” configuration
- T2 hyperintense bands (DM) and thinner isointense bands (preserved myelin)
- The center of the lesion usually shows no layering because of massive demyelination

# Key MRI features for the diagnosis of pseudotumoral IDLs

Baló-like pattern



Open-ring pattern



More than 50% of pseudotumoral ID lesions

**Open-ring enhancement**

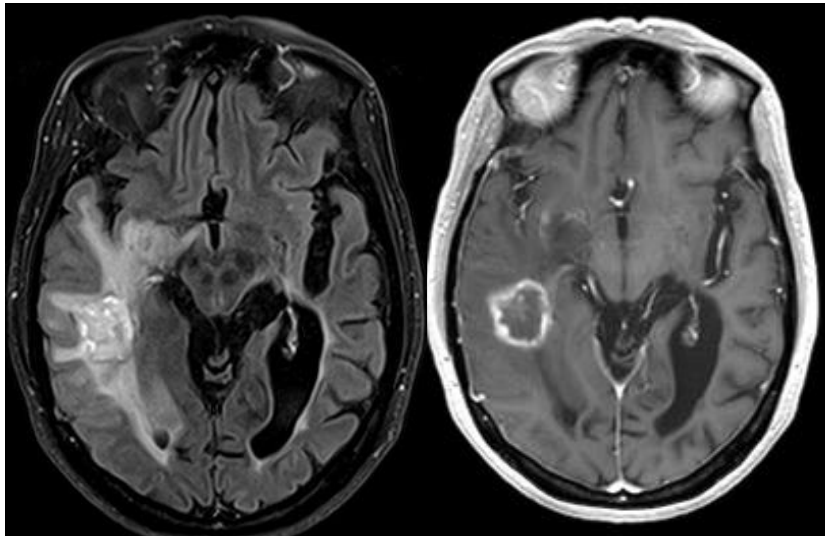
**Baló-like pattern**



# MRI in tumefactive lesions

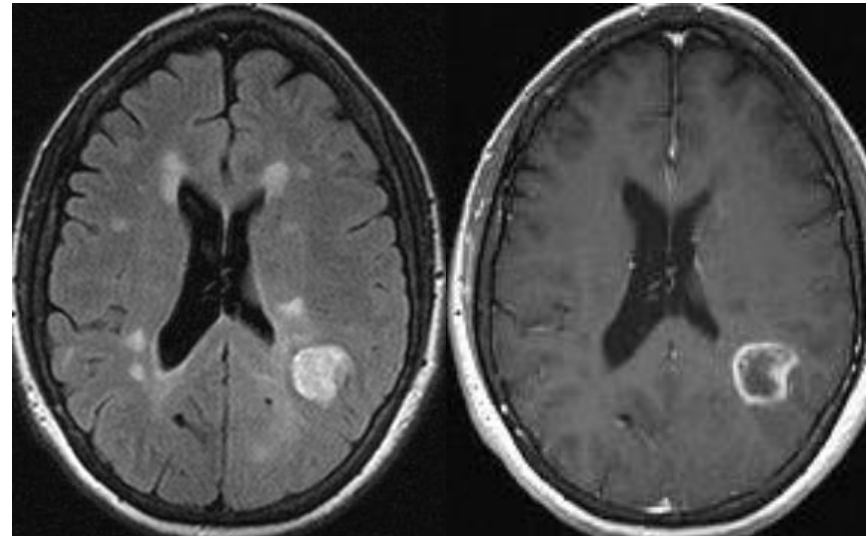
## Pseudotumoral inflammatory-demyelinating lesion? RRMS patients

Patient 1



47 year old woman  
RRMS  
30 years disease duration  
EDSS 5  
DMT  
Left side hemiparesis

Patient 2

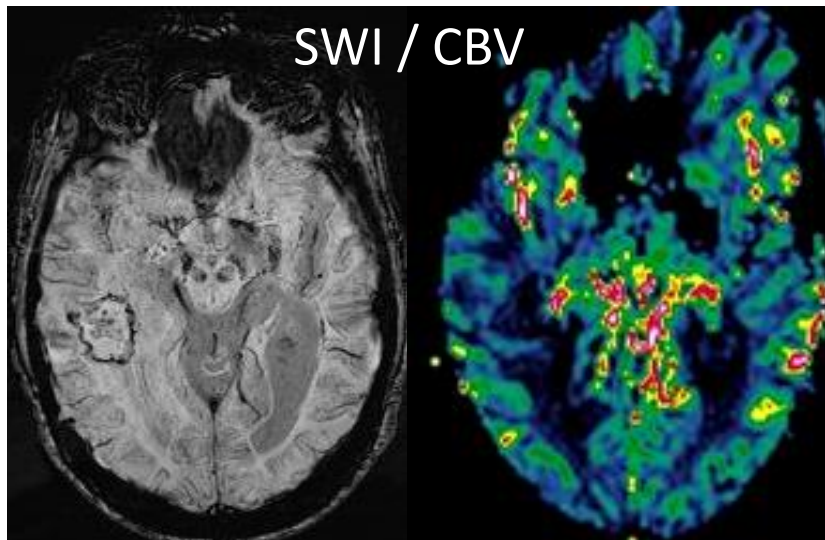


55 year old woman  
RRMS  
15 years disease duration  
EDSS 4  
DMT  
Seizures

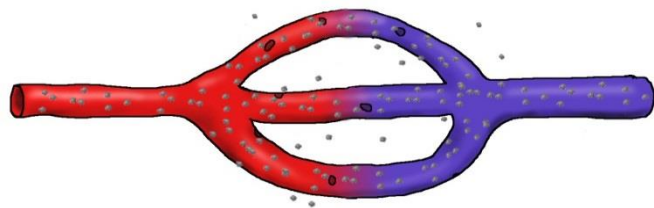
# MRI in tumefactive lesions

## Pseudotumoral inflammatory-demyelinating lesion? RRMS patients

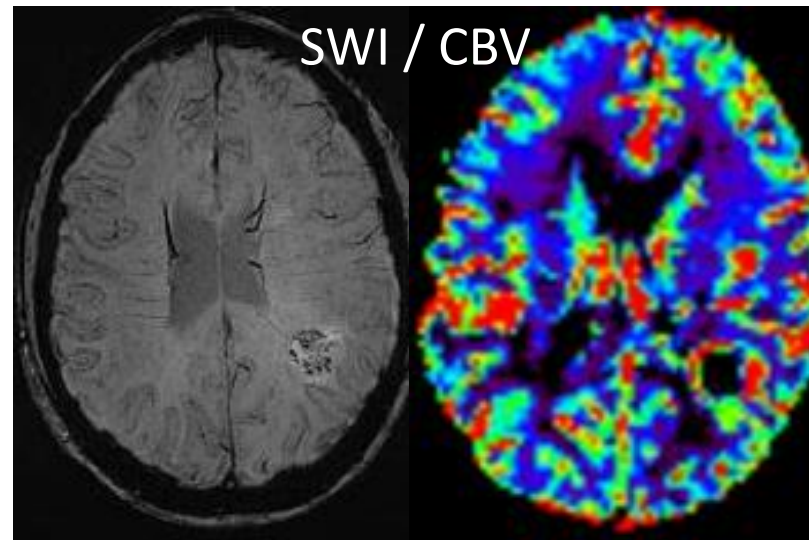
Patient 1



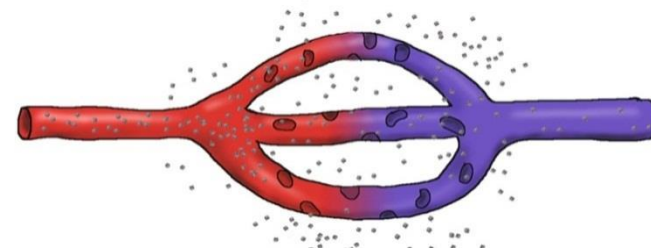
Low angiogenesis



Patient 2



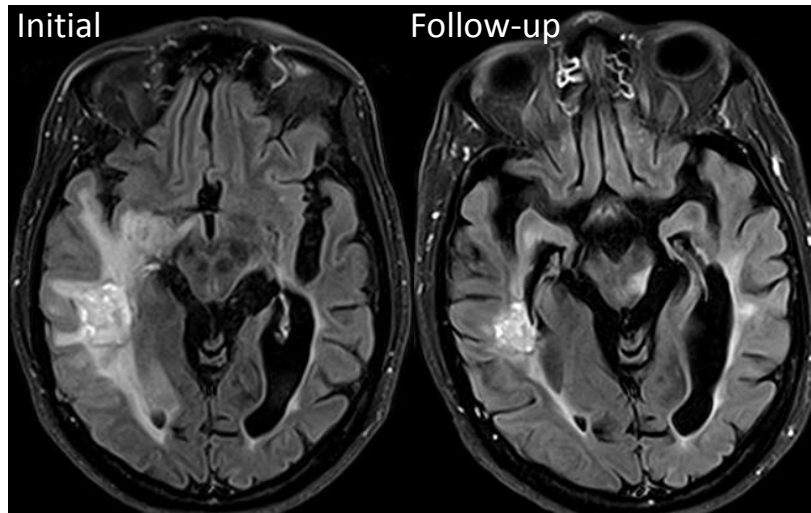
High angiogenesis



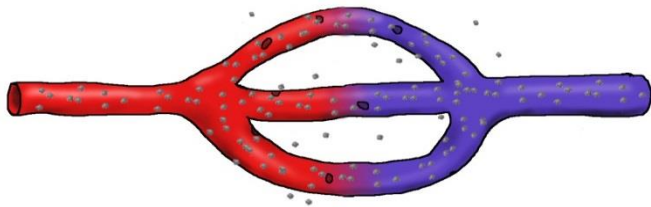
# Patterns of contrast uptake in tumefactive lesions

## Pseudotumoral inflammatory-demyelinating lesion? RRMS patients

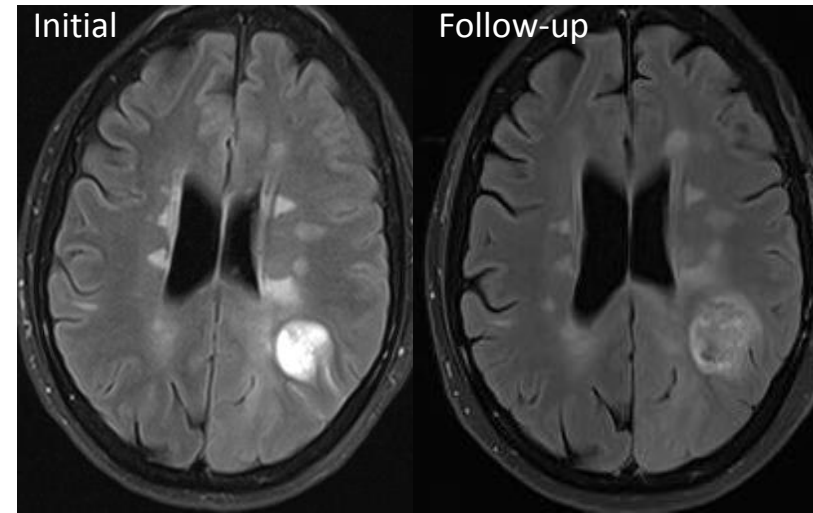
Patient 1: Pseudotumoral MS lesion



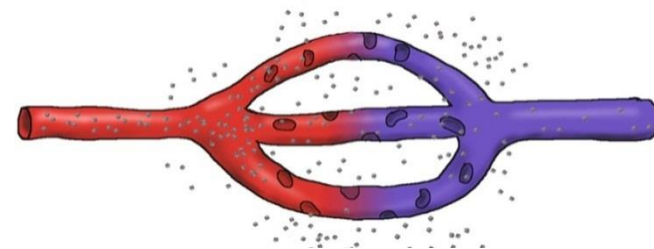
Low angiogenesis



Patient 2: Glioblastoma



High angiogenesis

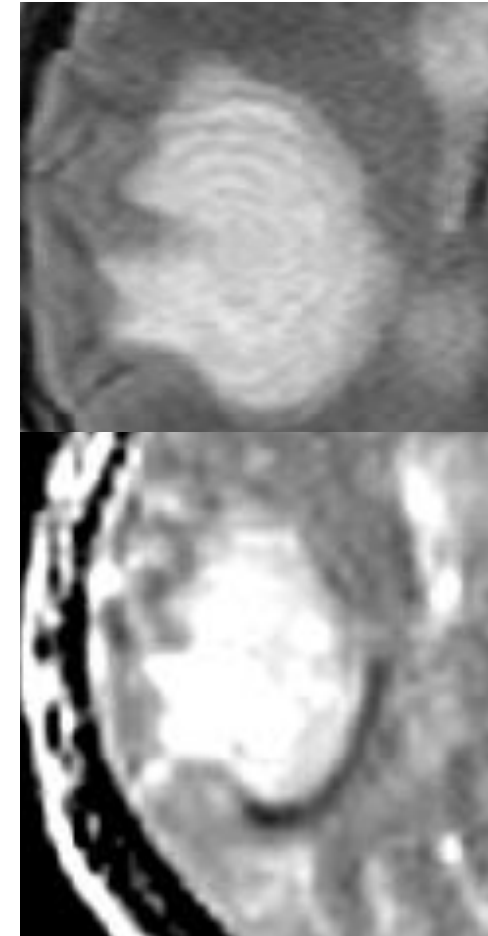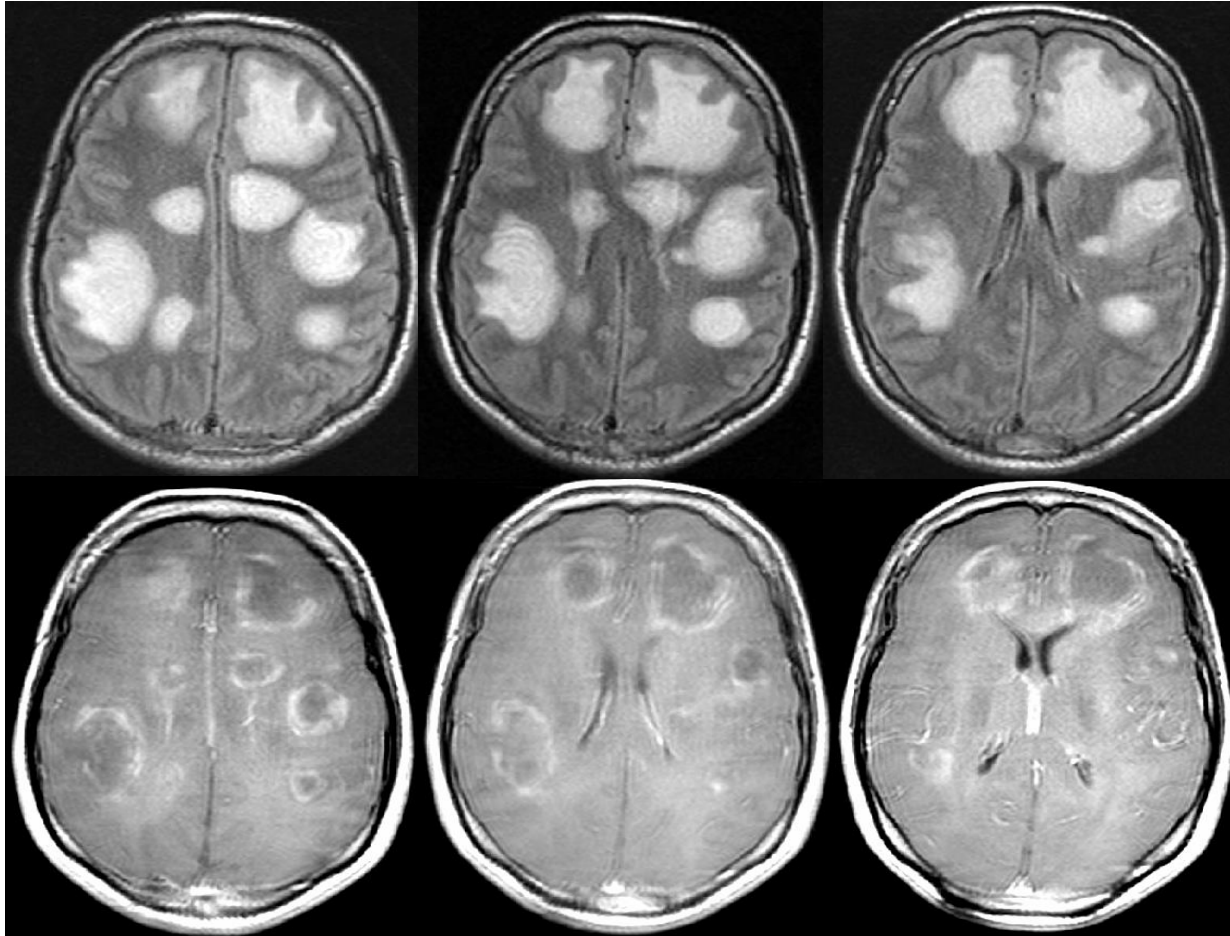




## Clinical case

A 39-year-old man,

- ✓ History of drug abuse (cocaine, cannabis and intravenous heroin)
- ✓ 3-weeks progressive course of dysarthria, fatigue, spatial disorientation, cognitive and behavioral dysfunction.
- ✓ HIV serology was negative.



Diagnosis?

1. Balo concentric sclerosis
2. Metastasis
3. Multifocal glioma
4. Toxic leukoencephalopathy

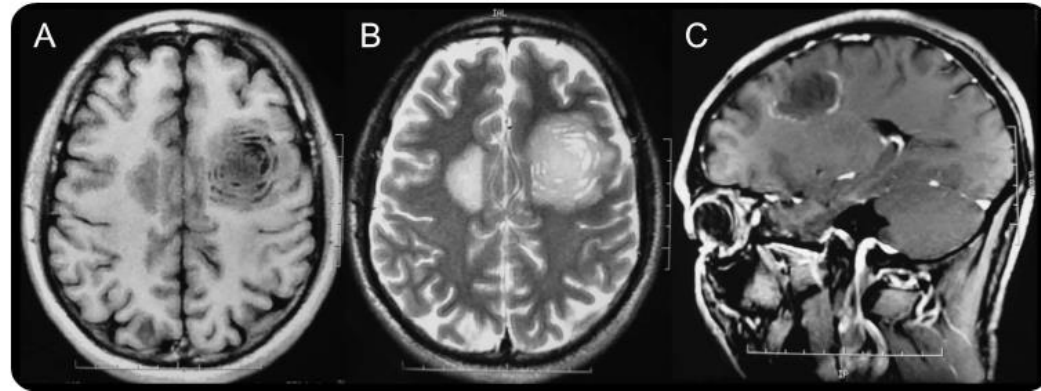
Diagnosis?

1. Balo concentric sclerosis
2. Metastasis
3. Multifocal glioma
4. **Toxic leukoencephalopathy**

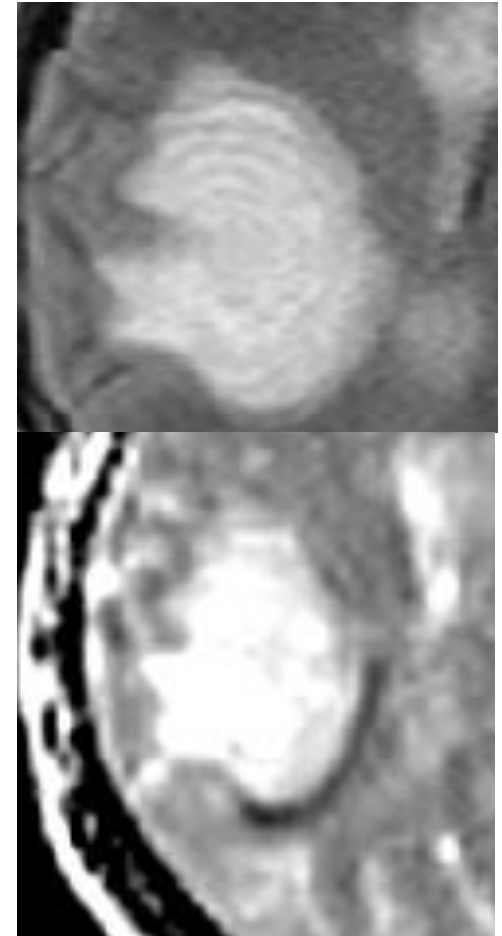


## Levamisole-induced leukoencephalopathy mimicking Baló disease

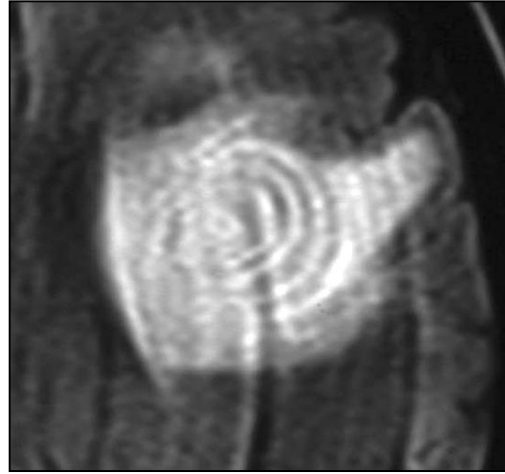
Figure Brain MRI in a patient with levamisole-induced leukoencephalopathy



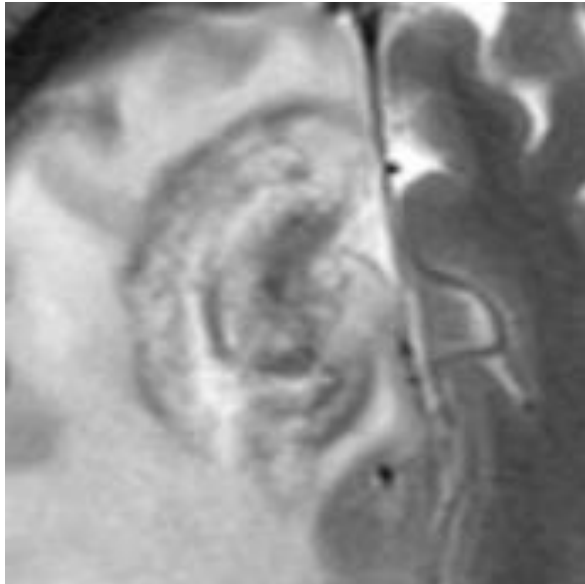
Long et al. Neurology 2015



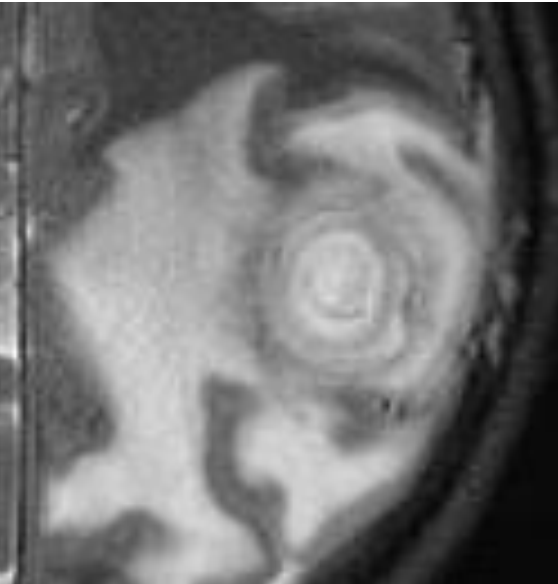# Concentric layer sign (Balo-like pattern)



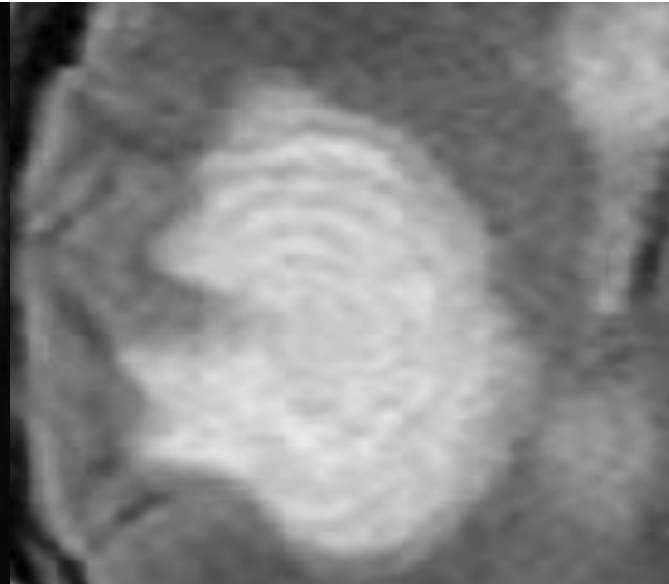
Balo concentric sclerosis



Toxoplasmosis



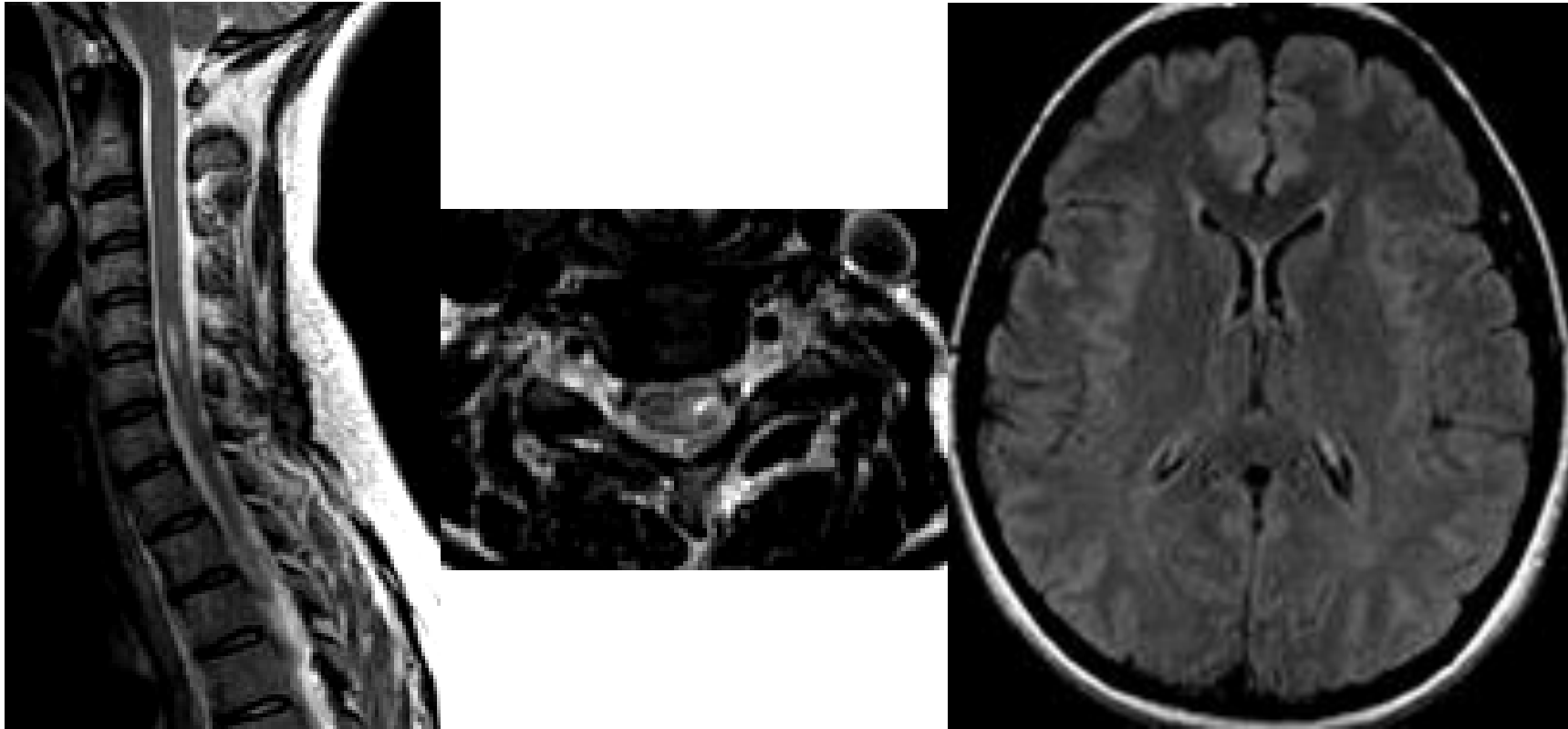
Pyogenic brain abscesses



Levamisole-associated multifocal  
inflammatory  
leukoencephalopathy (cocaine user)

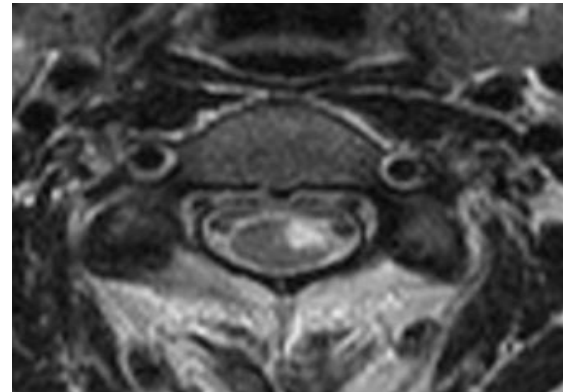
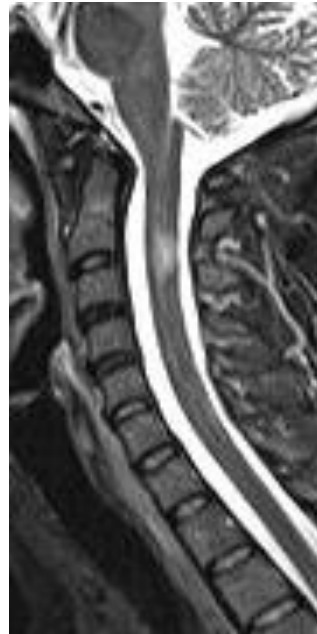## Clinical case

43 year old woman  
Acute partial TM



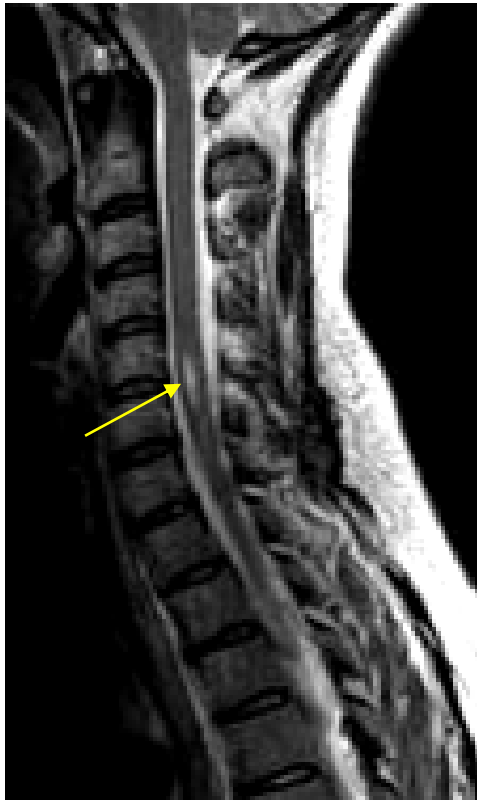## Typical MR imaging findings: spinal cord

- ✓ No cord swelling (unless active)
- ✓ Unequivocal hyperintense T2 or Gd-enhancing; focal lesions
- ✓  $\geq 3\text{mm}$  in size;  $< 2$  vertebral segments long
- ✓ Peripheral location, cigar shaped
- ✓ Occupying only part of cord cross-section (less than 50%)

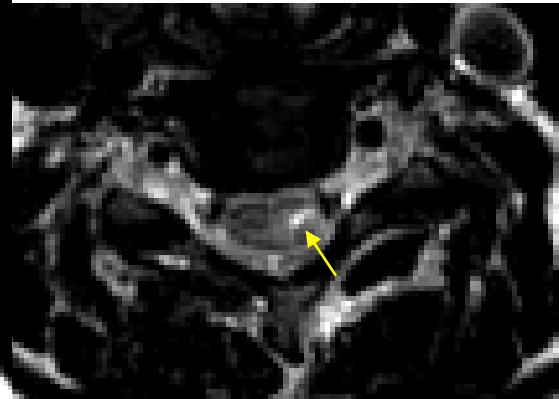


# Clinical case

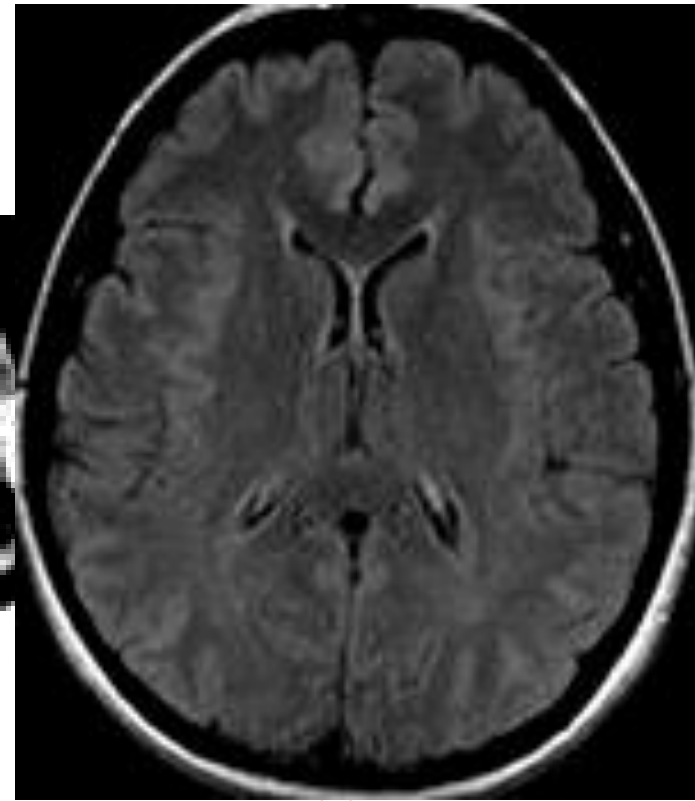
43 year old woman  
Acute partial TM



Short segment



Bright lesion



Normal brain MRI

Diagnosis?

1. Multiple sclerosis
2. NMOSD
3. Spinal cord infarct
4. Idiopathic transverse myelitis

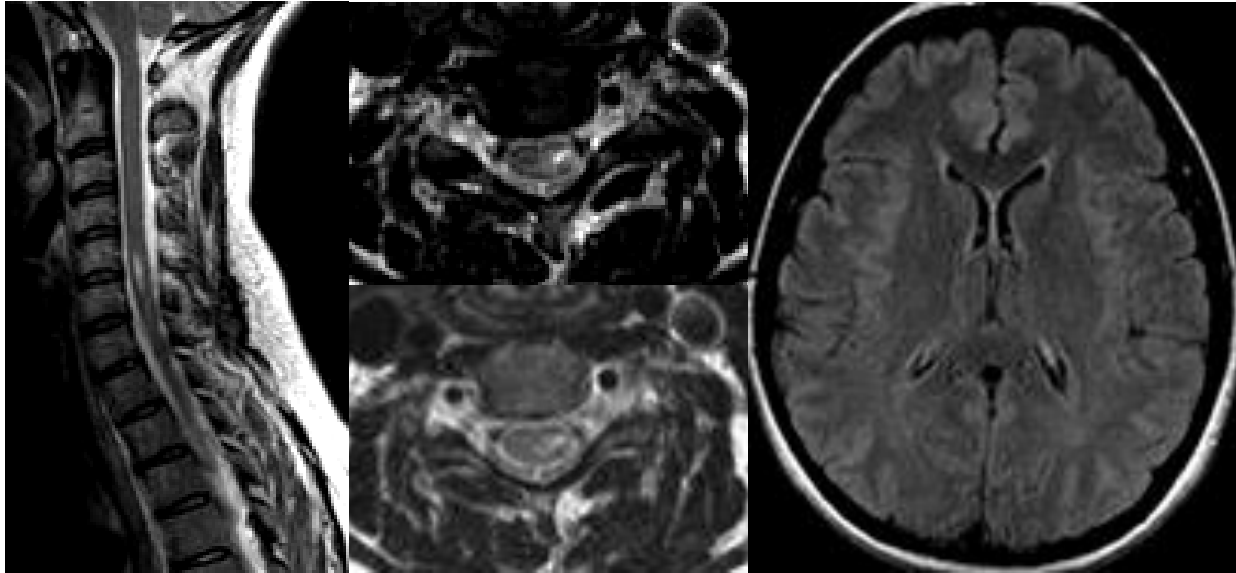


Diagnosis?

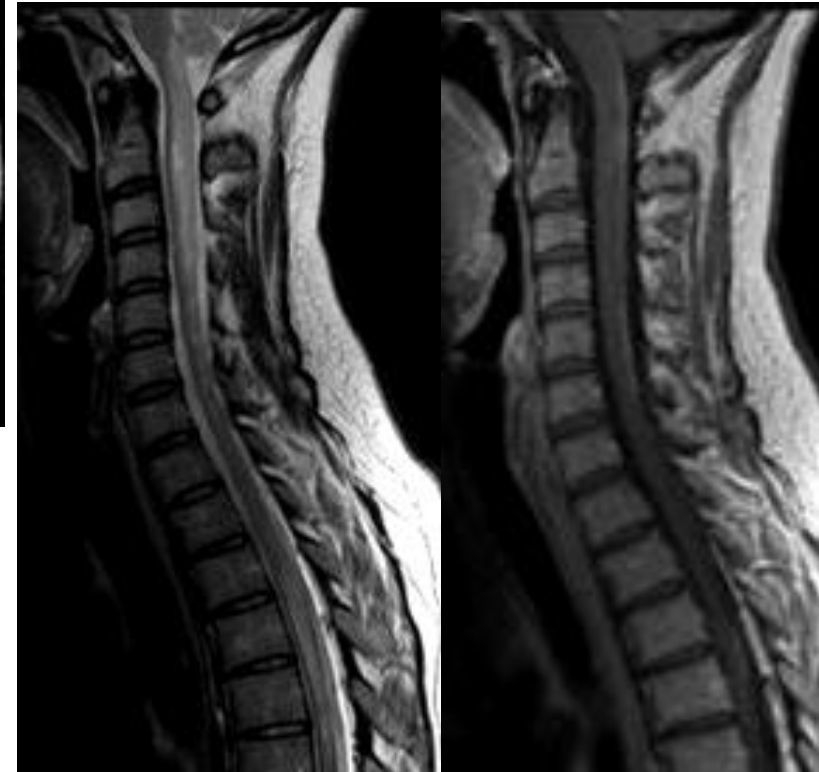
1. Multiple sclerosis
2. **NMOSD**
3. Spinal cord infarct
4. Idiopathic transverse myelitis

# Clinical case

43 year old woman  
Acute partial TM

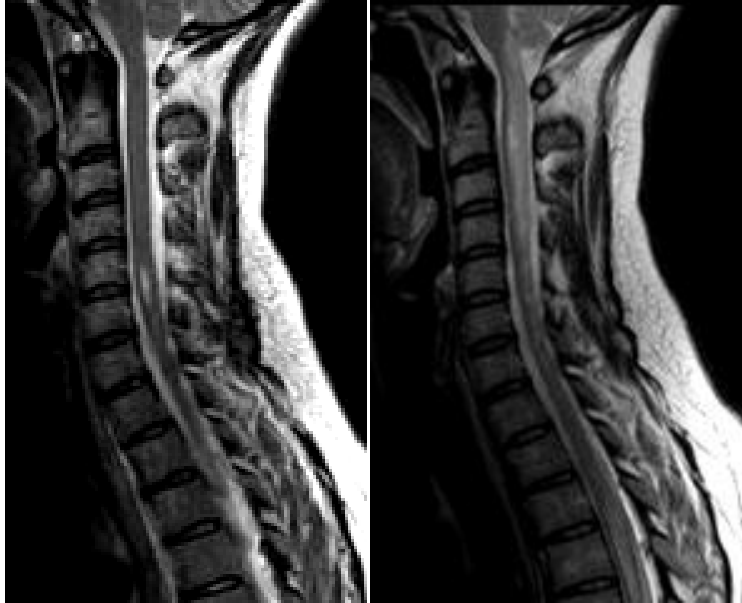

3 months later



AQP4 Ab +

## Short Myelitis Lesions in Aquaporin-4-IgG Positive NMOSD



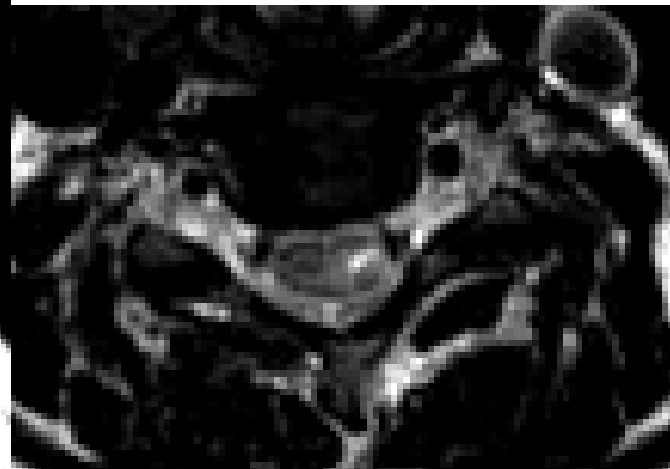
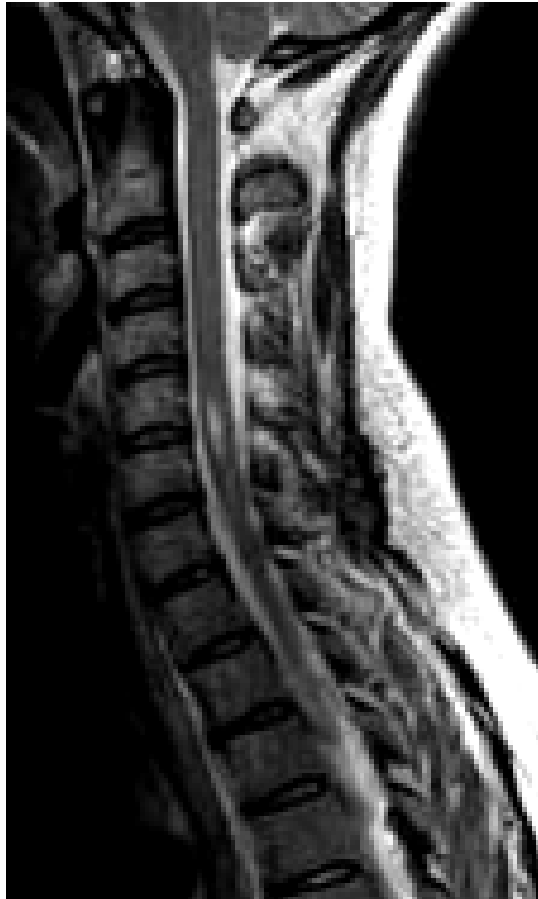- 25 patients (Mayo Clinic): 14% of initial myelitis episodes (NMOSD)
- Subsequent LETM in 92%
- Characteristics (compared to short myelitis lesions in Aquaporin-4-IgG negative):
  - coexisting autoimmunity
  - central cord lesions on MRI
  - T1 hypointensity
  - brain MRI inconsistent with MS
  - OB in CSF lacking

# Bright spotty lesions (BSLs) in NMO

- Very hyperintense spotty lesions on axial T2WI
- More hyperintense than that of surrounding cerebrospinal fluid

BSLs sensitivity = 54%; specificity = 97%  
LETM sensitivity = 67%; specificity=97%

BSLs or LETM: sensitivity 88%



Yonezu T et al. Mult Scler 2013

# Summary

- Wide variety of causes may present with multifocal WM lesions
- MRI is the preferred imaging technique for diagnostic workup
- Radiological interpretation with demographic, clinical history, and lab findings
- Standardized brain (spinal cord) MRI protocol
- Comprehensive checklist for evaluation of WM spots is crucial